



# Short course of high dose steroids used for non-pulmonary indication like anaphylaxis caused flare up of tuberculosis & presenting as acute pulmonary tuberculosis with pleural effusion: a case report

Shital Patil<sup>1</sup>, Gajanan Gondhali<sup>2</sup>

## ABSTRACT

Tuberculosis (TB) remains a major health problem in India, and accounts for nearly 20-30% of the global TB burden. Prevalence of tuberculosis infection in India is 40%, with pulmonary tuberculosis accounts for 80% cases, and in immune-competent individuals 5 to 10% chance of TB progressing from infection to disease during their lifetimes. Data is available for possible role of steroids used for pulmonary and non-pulmonary indications in increasing risk of new tuberculosis infection, reactivation of latent tuberculosis infection and relapse of treated disease. In this case report, 25 year male received high dose intravenous steroids for life threatening anaphylaxis because of bee sting bite only for four days caused reactivation of latent tuberculosis infection (LTBI). Clinical presentation is acute form of progressive pulmonary tuberculosis with pleural effusion which can be misdiagnosed as a community acquired pneumonia. High index of suspicion with adequate evaluation is must in all cases to have satisfactory treatment outcome.

**Keywords:** high dose steroids, pulmonary tuberculosis, LTBI

## INTRODUCTION

More than 30% of population in India is infected with tubercle bacilli (1), and accounts for nearly 20-30% of the global TB burden. After TB infection, active disease develops in 3 to 5% of "immune-competent" individuals within 2 years (defined as *progressive primary TB*, which is seen more commonly in patients with a large inoculation or immunosuppression), whereas active TB disease develops in an additional 3 to 5% of infected persons during the remainder of their life time (2).

Corticosteroids, through their immunosuppressive and anti-inflammatory effects, impair antibody formation and cell mediated immunity. Through these actions, steroids predispose patients to a variety of secondary infections including reactivation of latent tuberculous foci and re-infection with *Mycobacterium tuberculosis* (3, 4).

In this case report, we observed reactivation tuberculosis with the use of short course of steroids used for non-pulmonary indication.

## CASE SUMMARY

25 year male, non-alcoholic, Non tobacco addict, presented to Intensive care unit with history of more than 100 honey bee sting bite with high grade fever, shortness of breath and convulsions for 3 hours. On examination febrile (temp 102.5<sup>0</sup> F), restless, heart rate 110 bpm, respiration 20 pm, and Blood pressure 90/50 mmhg, tonic posturing of all four limbs with no obvious neurodeficit.

### **Routine evaluation was done as following-**

Complete Hemogram- Leukocytosis (total white blood cell count 18000/mm<sup>3</sup>), Hemoglobin 13 gm%, and Platelets 2.8 lacs

C reactive protein- titer 28.7/liter (positive)

<sup>1</sup> Venkatesh Chest Hospital & Assistant Professor, Pulmonary Medicine, MIMSR Medical College, Latur, India

<sup>2</sup> Internal Medicine, MIMSR Medical College, Latur, India

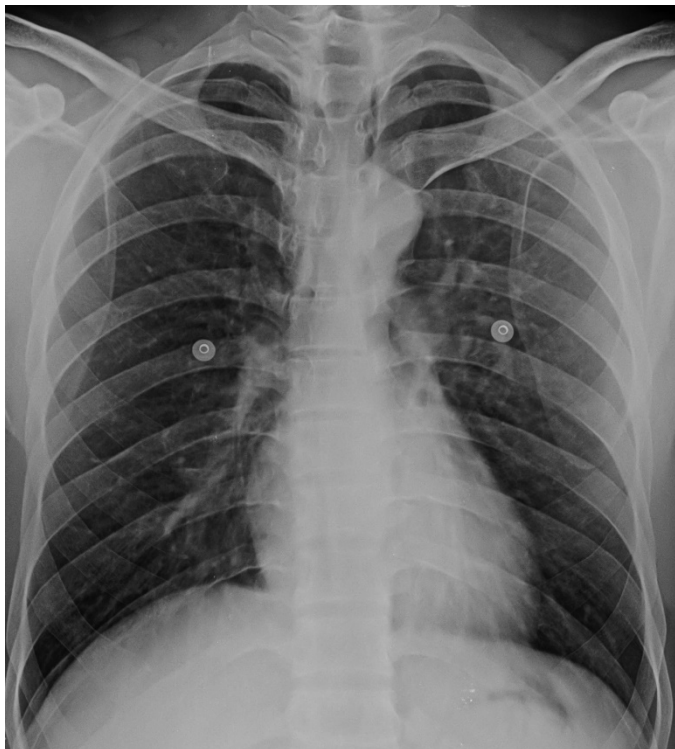Received: 07 Aug 2017, Accepted: 28 Sep 2017

**Correspondence:** Shital Patil

Assistant Professor & Head, Pulmonary Medicine, MIMSR Medical College, Latur, Maharashtra State, India

Phone: +917719036449, +919527028888

E-mail: [drsvpatil1980@gmail.com](mailto:drsvpatil1980@gmail.com)



**Figure 1:** Chest x-ray – Image 1

Blood sugar level, Liver function tests and kidney function tests are normal

**Chest x-ray - Image 1**-Showing normal lung parenchyma with normal hilum and cardiophrenic and costophrenic angles are clear.

He was managed in Intensive care unit, oxygen, inotropic agents were started. Received High dose Intravenous Methylprednisolone 125 mg stat and 40 mg maintenance three times a day, given for 3 days with tapering dose on 4<sup>th</sup> day. After 4 days of therapy, patient's vital parameters were normal, general condition was improved and discharged from hospital on 4<sup>th</sup> day of hospitalization.

After 2 weeks of discharge from hospitalization, patient developed acute onset pleuritic chest pain, localized to right lower axillary and infra-scapular and mammary area exaggerated on deep inspiration and relieved by breath hold. Additionally he was having cough with minimal sputum production, high grade fever, and shortness of breath grade II. On examination febrile, tachycardia and toxic presentation with normal respiratory rate and 98% oxygen saturation at room air. He was evaluated with hematological investigations and chest radiograph.

**Hemogram**- Hemoglobin 13.6 gm%, Total leucocyte count 9700/mm<sup>3</sup>, Platelets 5.25 lacs

Blood sugar level, liver function tests and kidney function tests were normal

ESR was 28 mm at the end of one hour

Sputum examination for gram stain was done showing multiple gram positive cocci in chains.

**Chest x-ray PA view- (after 2 weeks of high dose intravenous steroids for 4 days)**

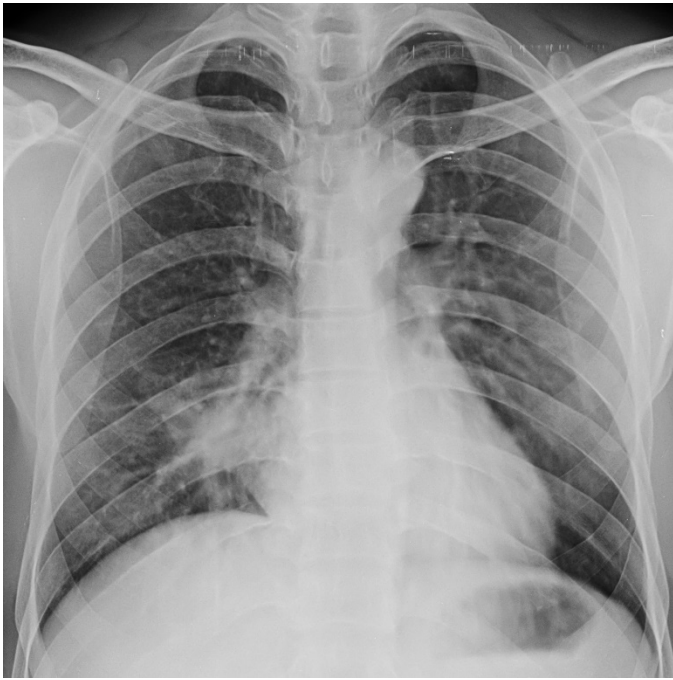**Image 2**-Showing right lower zone opacification/consolidation obscuring right heart border suggests consolidation of right middle lobe.

Received intravenous Antibiotics third generation cephalosporin's as hospital protocol for community acquired pneumonia, repeated total counts and chest x-ray because of partial relief of symptoms. Hemogram was again showing normal white blood cell count, sputum for gram stain was same picture and Zeihl Nelson stain negative for Acid fast bacilli.

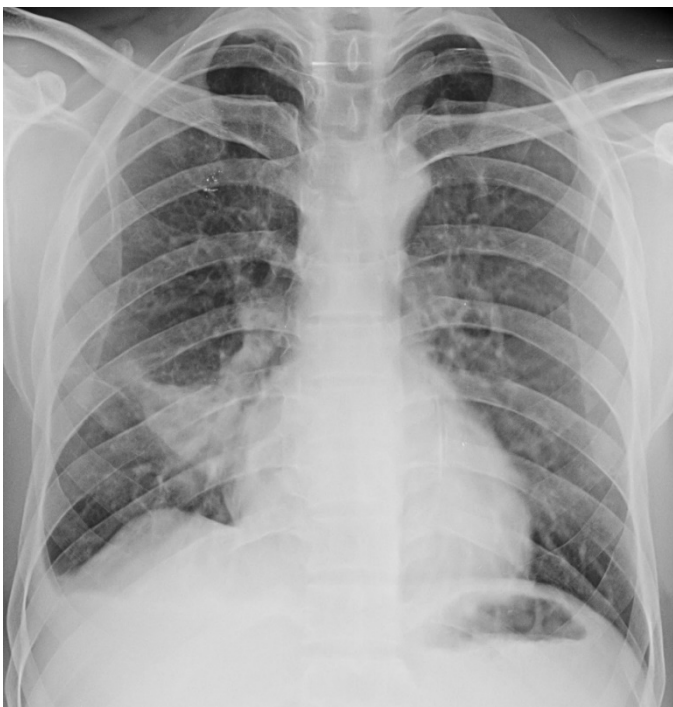**Chest x-ray after 48 hours of antibiotics therapy-**

**Image 3**-Showing worsening of parenchymal opacity with obliteration of costophrenic angle right side suggestive of pleural effusion. Classical 'tongue shape' opacity of right middle lobe collapse, crowding of right lower zone ribs and shift of diaphragm. Also note horizontal line of pleural fluid just behind the diaphragm.

We planned bronchoscopy to look for any endobronchial or peribronchial pathology causing right middle lobe collapse.



**Figure 2:** Chest x-ray PA view- (after 2 weeks of high dose intravenous steroids for 4 days) – Image 2



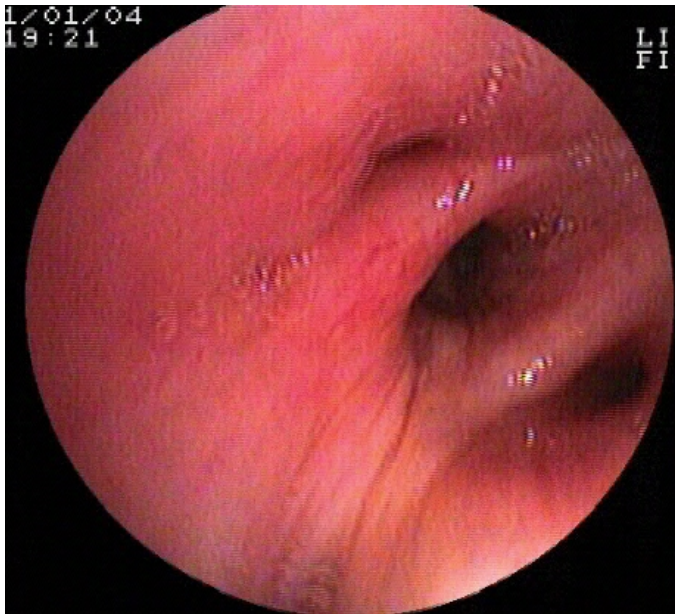
**Figure 3:** Chest x-ray after 48 hours of antibiotics therapy – Image 3

**Bronchoscopy image-Image 4-** Bronchoscopy image showing narrowed lumen of right middle lobe bronchus opening with increased rugosity. There is no clear endobronchial growth, but peribronchial compression due to lymph node enlargement is possible cause for narrowing and right lobe presentation on chest x-ray. We performed Transbronchial aspiration (TBNA) of bulge seen intraluminal from extrinsic compression and taken three transbronchial lung biopsies (TBLB) from right middle lobe.

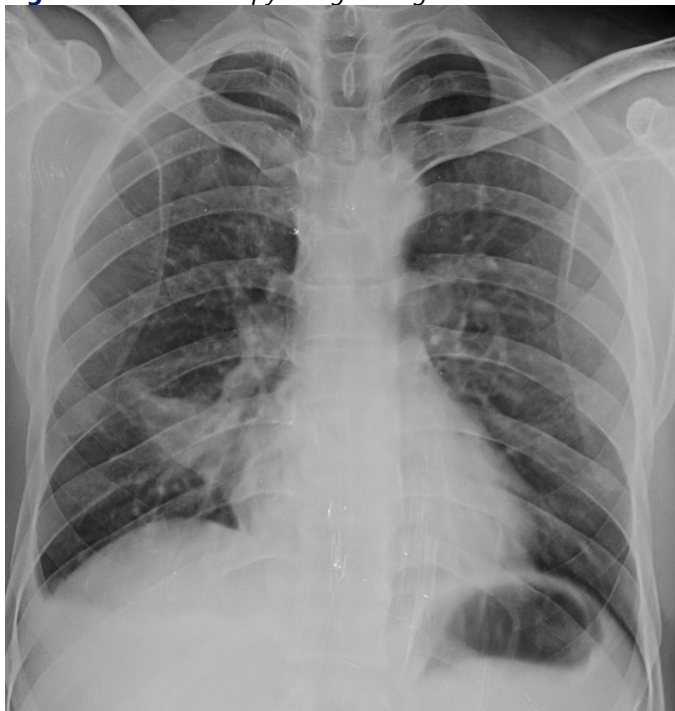**TBNA cytology** yields cellular material comprises of lymphocyte and macrophages without any evidence of granuloma, acid fast bacilli or histiocytes or any giant cells. There was no evidence of tuberculosis or malignancy.

**TBLB histopathology samples showing- Image 5** HPE 1- Epithelioid granuloma with giant cell

Histopathology sections of Bronchoscopic Transbronchial lung biopsy specimen shows bronchial mucosa along with separate fragments of caseous necrosis and intense lymphocytic infiltrate and incompletely formed epithelioid granuloma with occasional giant cell.



**Figure 4:** Bronchoscopy image-Image 4



**Figure 5:** TBLB histopathology samples showing- Image 5

#### **Bronchial wash for Gene Xpert/MTB Rif analysis-**

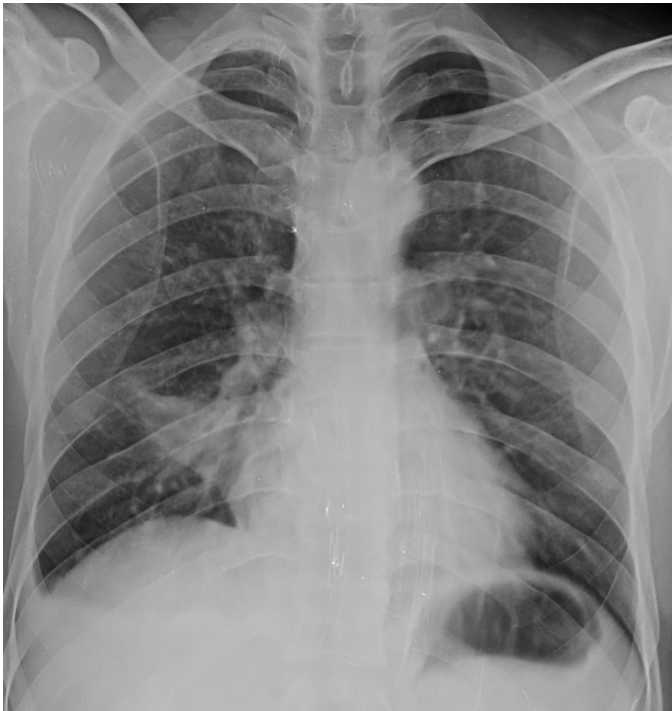Bronchial wash collected from right middle lobe and sent for Gene Xpert/MTB Rif analysis and showing MTB genome detection with negative rifampicin resistance, i.e. drug sensitive tuberculosis.

Started Anti-Tuberculosis treatment with Isoniazid, Rifampicin, pyrazinamide and Ethambutol daily therapy for 2 months intensive phase and Isoniazid with Rifampicin give for 4 months to complete 6 months standard regimen to treat tuberculosis.

**After 14 days of Anti tuberculosis therapy (Image 6)-** Showing response to anti-tuberculosis treatment was excellent, resolving 'right middle lobe syndrome' opacity i.e. right middle lobe collapse consolidation and decreased density of consolidation. Also note resolving pleural effusion on right side.

**Chest X-ray PA view-** (after 6 months of anti-tuberculosis treatment) **Image 7-** Showing near complete radiological resolution of parenchymal opacity with cardiophrenic and costophrenic angles clear. As compared to previous chest x-rays, after completion of anti-tuberculosis treatment there is no obvious residual pleural thickening at costophrenic angle, or any parenchymal lesion/opacity. There is 'thickening of oblique fissure' with diaphragmatic tenting on right side.





**Figure 6:** After 14 days of Anti tuberculosis therapy (Image 6)

## DISCUSSION

Corticosteroids, through their immunosuppressive and anti-inflammatory effects, impair antibody formation and cell mediated immunity. Through these actions, steroids predispose patients to a variety of secondary infections including reactivation of latent tuberculous foci and re-infection with *Mycobacterium tuberculosis* (3, 4).

The occurrence of TB also correlates with steroid dosing. One study even suggested that for each gram of prednisolone dose there was a 23% increment in the chance of developing TB (5). These effects are most evident if steroid doses exceed 0.03mg/kg/ day of Prednisolone or equivalent. At doses higher than 1 mg/kg/day, a marked increase in susceptibility to a wide variety of infections is experienced after several weeks. Treatment for less than 5 days appears to have less effect on immune function and predisposition to infections. Continuous therapy has longer and more profound immunosuppressive effects as compared to intermittent therapy (6).

Different systemic steroids, taken by mouth or given by injection, used in dermatology practice include hydrocortisone, prednisone, prednisolone, methylprednisolone, triamcinolone, dexamethasone and betamethasone. These differ in their relative anti-inflammatory and mineralocorticoid activity, plasma half-life and duration of ACTH suppression. Treatment regimen is called low-dose if <10mg/day prednisolone or equivalent is used and high-dose when >20mg prednisolone per day is prescribed. Similarly, steroid treatment is called short-term treatment when used for  $\leq 3$  weeks and long-term when given for >4 weeks (7).

The role of steroid therapy in precipitating tuberculosis is controversial, while some maintain that steroid therapy might cause exacerbation of active or apparently inactive tuberculosis (8).

### **Medical Conditions (Other than HIV) That Increase Risk of Progression of TB Infection (2):**

- Injection drug use
- Silicosis
- Diabetes mellitus
- Chronic renal failure
- Lymphomas, leukemias
- Cancers of the head, neck and lung
- Malnutrition (weight loss  $\geq 10\%$  below ideal body weight)
- Gastrectomy or jejunioileal bypass
- Children younger than 4 yr who are exposed to persons at high risk for TB
- Patients who receive immunosuppressive agents (including prednisone < 15 mg/d for < 1 month and TNF blocking agents)

In our case, initially patient was treated as an acute life threatening anaphylaxis with high dose intravenous steroids only for four days i.e. less than one week resulted in complete cure of that event but resulted in flare up of latent tuberculosis infection in 2 weeks post steroid and presented as acute pulmonary tuberculosis with pleural effusion. Clinical presentation of acute pulmonary tuberculosis was confusing with community acquired pneumonia and can be easily missed. Even right middle lobe presentation of acute pulmonary tuberculosis in less than a month is rarely described previously or very few data is available. We have evaluated with bronchoscopy, pleural fluid analysis and histopathology of Bronchoscopic biopsy specimens and confirmed to have tuberculosis is the etiology and treated with four drug anti-tuberculosis treatment containing Isoniazid, Rifampicin, Pyrazinamide and Ethambutol. Response to therapy was excellent with complete clinical and radiological response in six months of treatment.

#### **Steroids in tuberculosis- "double edge sword"**

Steroids are used during treatment of tuberculosis with cover of anti-tuberculosis drugs to prevent exaggerated response to tuberculous proteins shown by host immune system especially in pericardial, meningeal, miliary TB with hypoxemia and toxemia or fever persistent irrespective of treatment. Short course of steroids under cover of ATT shown excellent response and treatment outcome by its known anti-inflammatory effect.

Steroids also used for non-pulmonary or life threatening medical emergencies where duration and dosages are not fixed, although used for less than one week. Very few data is available, regarding possible role of steroids used for short course leading to reactivation of LTBI (latent tuberculosis infection).

#### **CONCLUSION**

Steroids will cause generalized immunosuppression and qualitative and quantitative local lung immune defense defect resulted in increased risk of tuberculosis either because of reactivation of latent infection or relapse or acquiring new infection. Risk of tuberculosis is proportional to use steroid dosage and duration either for pulmonary or non-pulmonary indication.

High index of suspicion is must to predict pulmonary tuberculosis because of confusing clinical pulmonary syndrome mimicking like community acquired pneumonia. Always consider tuberculosis as the cause of pulmonary infiltrates, consolidation or effusion in cases with history of use of steroids irrespective of dosage or duration to have successful treatment outcome.

Bronchoscopy is crucial in evaluation with histopathology expertise is must while managing such cases.

#### **REFERENCES**

1. Surpal BB. Magnitude of tuberculosis problem in India. J Ind Med Assoc. 1989;87:201.
2. American Thoracic Society, Centers for Disease Control and Prevention. Targeted tuberculin testing and treatment of latent tuberculosis infection. Am J Respir Crit Care Med. 2000;161:S221-S247.
3. Munck A, Mendel DB, Smith LI, Orti E. Glucocorticoid receptors and actions. Am Rev Respir. Dis. 1990;141:82.
4. Trehan AP, Ahmed A. Corticosteroids: a review with emphasis on complication of prolonged systemic therapy. Ann Allergy. 1989;62:375.
5. Tam LS, Li EK, Wong SM, Szeto CC. Risk factors and clinical features for tuberculosis among patients with systemic lupus erythematosus in Hong Kong. Scand J Rheumatol. 2002;31:296-300.
6. Wilson CB. The cellular immune system and its role in host defence. In: Mandel GL, Douglas RG Jr., Bennett JE: Eds. Principles and Practice of Infectious Disease. New York: Churchill Livingstone. 1990;101.
7. Mitsos L, Sasseville D. Systemic corticosteroid use in dermatology: defining, detailing, and demystifying. Dermatol Rounds. 2012;7-2.
8. Pal D, Behera D, Gupta D, Aggarwal A. Tuberculosis in patients receiving prolonged treatment with oral corticosteroids for respiratory disorders. Indian J Tub. 2002;49:83.



<http://www.ejgm.co.uk>