




Viable cesarean scar pregnancy from primary care perspective: A case report

Mohamad Syamilah¹ , Mohd Noor Norhayati^{1,2*} , Siti Suhaila Mohd Yusoff^{1,2} 

¹Department of Family Medicine, School of Medical Sciences, Universiti Sains Malaysia, Kubang Kerian, Kelantan, MALAYSIA

²Hospital Universiti Sains Malaysia, Kubang Kerian, Kelantan, MALAYSIA

*Corresponding Author: hayatik@usm.my

Citation: Syamilah M, Norhayati MN, Mohd Yusoff SS. Viable cesarean scar pregnancy from primary care perspective: A case report. Electron J Gen Med. 2024;21(3):em589. <https://doi.org/10.29333/ejgm/14631>

ARTICLE INFO

Received: 30 Aug. 2023

Accepted: 05 May 2024

ABSTRACT

Ectopic pregnancies within previous cesarean section scars are rare but potentially life-threatening complications. Diagnosis can be challenging, particularly in primary care settings, where the focus is often on routine primary care services. We present a case report of a patient who initially presented to a primary care clinic with non-specific symptoms of ectopic pregnancy and was referred to a tertiary center for incomplete miscarriage. It was found to be a viable ectopic pregnancy within a cesarean scar. This case highlights the importance of keeping an open mind in patients with a history of cesarean section and uterine manipulation procedures such as manually evacuating a retained placenta. It emphasizes prompt diagnosis and referral to a specialized healthcare facility.

Keywords: cesarean section, pregnancy, ectopic, prenatal care, pregnancy complication

INTRODUCTION

Ectopic pregnancy is defined as the implantation of a fertilized ovum outside the uterine cavity. It is a relatively uncommon event, accounting for one in every 193 pregnancies [1]. However, it is associated with substantial risks of severe maternal morbidity and mortality [2]. Cesarean scar ectopic pregnancies refer to gestational sac implants into the previous scar area at different degrees of trophoblastic invasion and penetration. It is even less common, with an estimated incidence of 1:1,800 to 1:2,226 total pregnancies [3], and accounts for 6% of ectopic pregnancies among women who have had a prior cesarean delivery [4]. It can be challenging to diagnose cesarean scar pregnancies because of their rarity and unique presentation, especially in primary care settings, where the initial evaluation is frequently centered on standard general care services. Severe consequences, including uterine rupture, bleeding, and maternal morbidity or mortality, can result from the delayed or missing identification of cesarean scar pregnancies [5].

CASE REPORT

A 32-year-old woman with gravida five, para four, presented twice to a primary care clinic complaining of lower abdominal pain and irregular vaginal bleeding. She had a history of previous cesarean sections ten years ago and manual removal of retained placenta three years ago. Her first presentation was at six weeks, one-day period of gestation. Urine pregnancy test was positive, and she was diagnosed as missed miscarriage and given an appointment at a gynecology

clinic two weeks later. Unfortunately, she presented again for a second episode of vaginal bleeding at seven weeks gestation. She was referred to the gynecology team for a suspected incomplete miscarriage. Upon review, the patient appeared stable. Abdominal examination revealed a soft abdomen, with tenderness on deep palpation over the suprapubic region. The uterus was not palpable. On speculum and vagina examination, the vulva and vagina appeared normal. The cervix was 2.00×2.00 cm, tubular, smooth surface, and healthy. The os appeared closed. There were minimal old blood stains at the os, but no active bleeding was observed. Cervical excitation was negative, and there was no fullness in the pouch of Douglas. No adnexal mass was felt. A bimanual examination indicated that the uterus was approximately eight weeks in size.

Initial assessment by transabdominal ultrasonography (TAS) showed intrauterine collection with thickened endometrial lining without a fetal echo. Given the non-specific nature of the symptoms and obstetric history of cesarean section as well as manual removal of placenta, the physician decided to conduct a transvaginal ultrasound.

Transvaginal ultrasonography (TVS) revealed an intrauterine collection with mixed echogenicity measuring 6.50×2.30 cm. It had a continuity with the gestational sac bulging anteriorly located just posterior to the bladder. It exhibited the presence of a yolk sac and fetal heart activity with a crown-rump length (CRL) of 0.67 cm, corresponding to six weeks and four days of gestation. No color doppler uptake was detected inside the intrauterine collection. However, the uptake was observed as circumferential to the gestational sac. The bladder was well demarcated posteriorly, with a thickness between the bladder and the gestational sac of 0.25 cm.

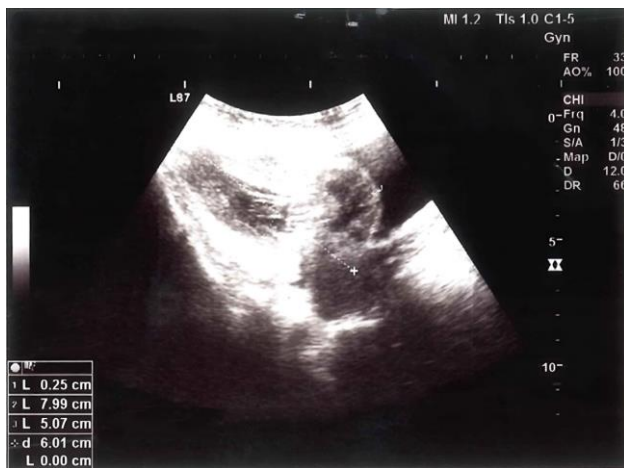


Figure 1. TAS of anteverted uterus with intrauterine collection (uterus measured by 7.99×5.07 cm with well-demarcated bladder anteriorly; thickness between gestational sac & urinary bladder is 0.25 cm) (reprinted with permission of the patient)

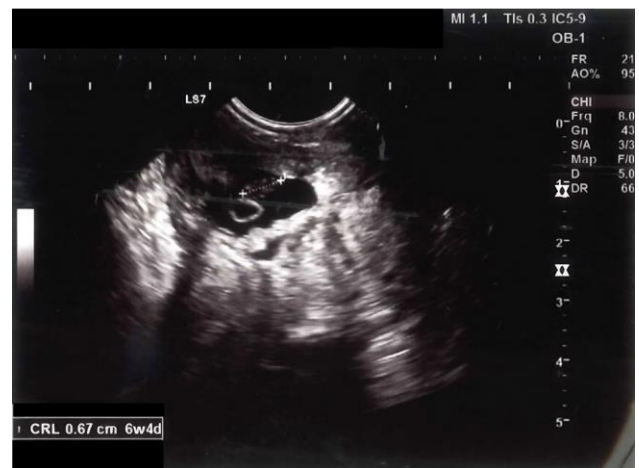

Figure 3. Yolk sac & CRL 0.67 cm correspond to six weeks four days gestation located just posterior to urinary bladder (reprinted with permission of the patient)

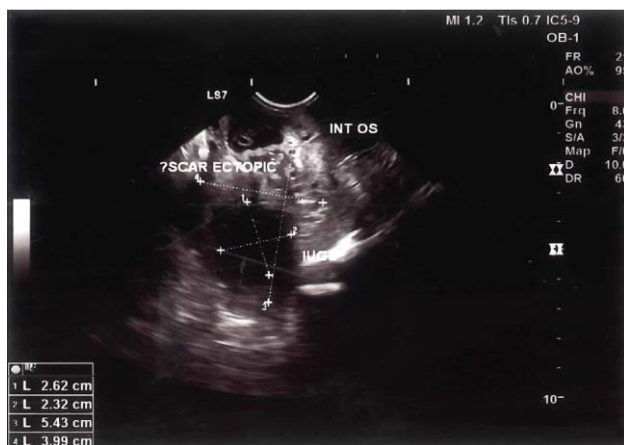

Figure 2. TVS of cesarean scar ectopic pregnancy in relation to intrauterine collection & internal os (intrauterine collection measured by 2.62×2.32 cm) (reprinted with permission of the patient)

Otherwise, the uterus was anteverted, measuring 7.99×5.07 cm. No free fluid was seen. The right ovary measured 2.50×2.00 cm and exhibited a corpus luteal cyst measuring 1.60×1.00 cm, while the left measured 1.00×2.30 cm. The beta-human chorionic gonadotropin (BHCG) level was 33,364 IU/L. Thus, commit to a viable cesarean scar pregnancy.

Figure 1 shows TAS of anteverted uterus with intrauterine collection.

Figure 2 depicts TVS of cesarean scar ectopic pregnancy in relation to intrauterine collection and internal os.

Figure 3 shows the yolk sac and CRL 0.67 cm correspond to six weeks four days gestation located just posterior to the urinary bladder.

The patient underwent a medical treatment modality by administration of 100 mg of potassium chloride directly into the fetal heart via ultrasound-guided. Following this, two doses of methotrexate were injected intramuscularly on the first and fourth days. Her clinical condition remained stable following the methotrexate injections. However, BHCG levels showed no significant changes during the first week after methotrexate administration. Subsequent follow-ups revealed a progressive

decreasing trend in BHCG levels, and at day 85, BHCG levels became normalized. After careful consideration, she was prescribed an injectable hormonal contraceptive to ensure effective birth control. She has emphasized the importance of avoiding pregnancy for at least six months after administering methotrexate. Additionally, she was emphasized the significance of early antenatal booking once pregnancy is confirmed because of a high incidence of ectopic site gestations in subsequent pregnancies.

DISCUSSION

This is a situation, where primary care providers miss a pregnancy with an ectopic cesarean scar. The primary care setting is crucial in identifying and managing early pregnancy. In this case, however, the initial diagnosis of missed miscarriage highlights the difficulty in identifying a cesarean scar ectopic pregnancy, as the differential diagnosis can include both missed miscarriage and incorrect dates. Multiple factors may have contributed to the failure to recognize this presentation's uniqueness.

The patient's history of prior cesarean sections and manual removal of a retained placenta should have prompted initial suspicions of a possible ectopic cesarean scar pregnancy [5]. The risk factors increase the probability of aberrant implantation and should prompt a high suspicion index. Primary care providers should be aware of the link between cesarean scar pregnancies and a history of cesarean section and uterine manipulation procedures.

Second, the non-specific symptoms often mimic other common conditions, leading to potential delays in diagnosis. The patient's symptoms, including lower abdominal pain and irregular vaginal bleeds, are typical of normal early pregnancies, ectopic pregnancies, and miscarriages. Without additional research, distinguishing between these presentations cannot be easy. However, an evaluation, including a thorough medical history and physical examination, can assist in identifying potential red flags and prompt appropriate investigations. Maintaining a high index of suspicion, especially in patients with a history of cesarean section and uterine manipulation procedures, is crucial for

timely identification and referral to appropriate specialist care [6].

The initial transabdominal ultrasound did not detect the ectopic pregnancy. Transabdominal ultrasound has limitations in detecting cesarean scar ectopic pregnancies, whereas transvaginal ultrasound is the gold standard for diagnosis [5]. Magnetic resonance imaging has to be considered when sonography is equivocal or inconclusive [7]. A timely referral for a transvaginal ultrasound could have resulted in an earlier diagnosis, given the patient's risk factors and the persistence of symptoms.

Management of ectopic cesarean scar pregnancies calls for a multidisciplinary approach involving gynecologists, radiologists, and primary care physicians. Primary care providers must recognize clinical indicators and promptly refer patients to the appropriate specialists for further evaluation and treatment. To increase the recognition of ectopic cesarean scar pregnancies in primary care, healthcare providers should receive adequate education and training on identifying high-risk patients, comprehending the unique clinical presentations, and using diagnostic tools appropriately. Early recognition and referral can assist in avoiding complications associated with this uncommon but potentially fatal condition [5].

CONCLUSIONS

This case report emphasizes the importance of appropriately recognizing and managing ectopic cesarean scar pregnancies from a primary care perspective. Primary care providers must maintain a high index of suspicion, particularly with patients with risk factors such as a history of cesarean section. Accurate diagnosis and optimal management of these unique pregnancies require prompt referral for transvaginal ultrasound and collaboration with specialists

Author contributions: All authors have sufficiently contributed to the study and agreed with the results and conclusions.

Funding: No funding source is reported for this study.

Acknowledgements: The authors would like to thank the patient for her participation.

Ethical statement: The authors stated that ethical approval was not required for this study. Informed consent was obtained from the

patient. However, no particulars of the patient will be exposed or can be identified & ensure that the information is for educational purposes only.

Declaration of interest: No conflict of interest is declared by the authors.

Data sharing statement: Data supporting the findings and conclusions are available upon request from the corresponding author.

REFERENCES

- Berhe ET, Kiros K, Hagos MG, Gesesew HA, Ward PR, Gebremeskel TG. Ectopic pregnancy in Tigray, Ethiopia: A cross-sectional survey of prevalence, management outcomes, and associated factors. *J Pregnancy*. 2021;2021:4443117. <https://doi.org/10.1155/2021/4443117> PMID:34888104 PMCID:PMC8651379
- Petersen KB, Hoffmann E, Larsen CR, Nielsen HS. Cesarean scar pregnancy: A systematic review of treatment studies. *Fertil Steril*. 2016;105(4):958-67. <https://doi.org/10.1016/j.fertnstert.2015.12.130> PMID:26794422
- Roche C, McDonnell R, Tucker P, et al. Cesarean scar ectopic pregnancy: Evolution from medical to surgical management. *Aust N Z J Obstet Gynaecol*. 2020;60(6):852-7. <https://doi.org/10.1111/ajo.13241> PMID:32820539
- Ndubizu C, McLaren Jr RA, McCalla S, Irani M. Recurrent cesarean scar ectopic pregnancy treated with systemic methotrexate. *Case Rep Obstet Gynecol*. 2017;2017:9536869. <https://doi.org/10.1155/2017/9536869> PMID:29333307 PMCID:PMC5733213
- Miller R, Gyamfi-Bannerman C, Medicine SfM-F, Committee P. Society for maternal-fetal medicine consult series# 63: Cesarean scar ectopic pregnancy. *AJOG*. 2022;227(3):9-20. <https://doi.org/10.1016/j.ajog.2022.06.024> PMID: 35850938
- Itani S, Jabin M, Dasara H, Forehand K, DePrisco G. Diagnosis and management of cesarean scar ectopic pregnancy: A case study. *Cureus*. 2023;15(9):e45160. <https://doi.org/10.7759/cureus.45160>
- Seah S-C, Laili S, Hairiah A, Ab Rahim A. Catching an ectopic caesarean scar pregnancy: Radiological perspective. *Med J Malays*. 2018;73(1):51-3. PMCID:29531205